

International Association of Dental Traumatology guidelines for the management of traumatic dental injuries: 1. Fractures and luxations

Cecilia Bourguignon¹  | Nestor Cohenca²  | Eva Lauridsen³  |
 Marie Therese Flores⁴  | Anne C. O'Connell⁵  | Peter F. Day⁶  |
 Georgios Tsilingaridis^{7,8}  | Paul V. Abbott⁹  | Ashraf F. Fouad¹⁰  | Lamar Hicks¹¹ |
 Jens Ove Andreasen¹² | Zafer C. Cehrelil¹³ | Stephen Harlamb¹⁴ | Bill Kahler¹⁵  |
 Adeleke Oginni¹⁶ | Marc Semper¹⁷ | Liran Levin¹⁸ 

¹Specialist Private Practice, Paris, France

²Department of Pediatric Dentistry, University of Washington and Seattle Children's Hospital, Seattle, WA, USA

³Resource Center for Rare Oral Diseases, Copenhagen University Hospital, Copenhagen, Denmark

⁴Department of Pediatric Dentistry, Faculty of Dentistry, Universidad de Valparaíso, Valparaíso, Chile

⁵Paediatric Dentistry, Dublin Dental University Hospital, Trinity College Dublin, The University of Dublin, Dublin, Ireland

⁶School of Dentistry, University of Leeds and Community Dental Service Bradford District Care NHS Trust, Leeds, UK

⁷Division of Orthodontics and Pediatric Dentistry, Department of Dental Medicine, Karolinska Institutet, Huddinge, Sweden

⁸Center for Pediatric Oral Health Research, Stockholm, Sweden

⁹UWA Dental School, University of Western Australia, Nedlands, WA, Australia

¹⁰Adams School of Dentistry, University of North Carolina, Chapel Hill, NC, USA

¹¹Division of Endodontics, University of Maryland School of Dentistry, UMB, Baltimore, MD, USA

¹²Department of Oral and Maxillofacial Surgery, Resource Centre for Rare Oral Diseases, University Hospital in Copenhagen (Rigshospitalet), Copenhagen, Denmark

¹³Department of Pediatric Dentistry, Faculty of Dentistry, Hacettepe University, Ankara, Turkey

¹⁴Faculty of Medicine and Health, The University of Sydney, Sydney, NSW, Australia

¹⁵School of Dentistry, The University of Queensland, St Lucia, Qld, Australia

¹⁶Faculty of Dentistry, College of Health Sciences, Obafemi Awolowo University, Ile-Ife, Nigeria

¹⁷Specialist Private Practice, Bremen, Germany

¹⁸Faculty of Medicine and Dentistry, University of Alberta, Edmonton, AB, Canada

Correspondence

Liran Levin, Chair of the IADT Guidelines Committee, Faculty of Medicine & Dentistry, University of Alberta, 5-468 Edmonton Clinic Health Academy, 11405 - 87 Avenue NW, 5th Floor, Edmonton, AB T6G 1C9, Canada.
 Email: liran@ualberta.ca

Abstract

Traumatic dental injuries (TDIs) of permanent teeth occur frequently in children and young adults. Crown fractures and luxations of these teeth are the most commonly occurring of all dental injuries. Proper diagnosis, treatment planning, and follow up are important for achieving a favorable outcome. Guidelines should assist dentists and patients in decision making and in providing the best care possible, both effectively and efficiently. The International Association of Dental Traumatology (IADT) has developed these Guidelines as a consensus statement after a comprehensive

This is an open access article under the terms of the Creative Commons Attribution-NonCommercial-NoDerivs License, which permits use and distribution in any medium, provided the original work is properly cited, the use is non-commercial and no modifications or adaptations are made.

© 2020 The Authors. *Dental Traumatology* published by John Wiley & Sons Ltd.

review of the dental literature and working group discussions. Experienced researchers and clinicians from various specialties and the general dentistry community were included in the working group. In cases where the published data did not appear conclusive, recommendations were based on the consensus opinions of the working group. They were then reviewed and approved by the members of the IADT Board of Directors. These Guidelines represent the best current evidence based on literature search and expert opinion. The primary goal of these Guidelines is to delineate an approach for the immediate or urgent care of TDIs. In this first article, the IADT Guidelines cover the management of fractures and luxations of permanent teeth. The IADT does not, and cannot, guarantee favorable outcomes from adherence to the Guidelines. However, the IADT believes that their application can maximize the probability of favorable outcomes.

KEYWORDS

avulsion, luxation, prevention, tooth fracture, trauma

1 | INTRODUCTION

The vast majority of traumatic dental injuries (TDI) occur in children and teenagers where loss of a tooth has lifetime consequences. Treatments for these younger age groups may be different than in adults, mainly due to immature teeth and pubertal facial growth. The purpose of these Guidelines is to improve management of injured teeth and minimize complications resulting from trauma.

2 | CLINICAL EXAMINATION

Trauma involving the dento-alveolar region is a frequent occurrence which can result in the fracture and displacement of teeth, crushing, and/or fracturing of bone, and soft tissue injuries including contusions, abrasions, and lacerations. Available current literature provides protocols, methods, and documentation for the clinical assessment of traumatic dental injuries (TDI), trauma first aid, patient examination, factors that affect treatment planning decisions, and the importance of communicating treatment options and prognosis to traumatized patients.¹⁻³

The combination of two different types of injuries occurring concurrently to the same tooth will be more detrimental than a single injury, creating a negative synergistic effect. Concurrent crown fractures significantly increase the risk of pulp necrosis and infection in teeth with concussion or subluxation injuries and mature root development.⁴ Similarly, crown fractures with or without pulp exposure significantly increase the risk of pulp necrosis and infection in teeth with lateral luxation.^{5,6}

Kenny et al⁷ have developed a core outcome set (COS) for TDIs in children and adults. Outcomes were identified as recurring throughout the different injury types. These outcomes were then identified as “generic” or “injury-specific.” Generic outcomes are relevant to

all TDIs while “injury-specific outcomes” are related to only one or more specific TDIs. Additionally, the core outcome set also established what, how, when, and by whom these outcomes should be measured (Tables 1-13).

3 | RADIOGRAPHIC EXAMINATION

Several conventional two-dimensional imaging projections and angulations are recommended.^{2,8,9} The clinician should evaluate each case and determine which radiographs are required for the specific case involved. A clear justification for taking a radiograph is essential. There needs to be a strong likelihood that a radiograph will provide the information that will positively influence the selection of the treatment provided. Furthermore, initial radiographs are important as they provide a baseline for future comparisons at follow-up examinations. The use of film holders is highly recommended to allow standardization and reproducible radiographs.

Since maxillary central incisors are the most frequently affected teeth, the radiographs listed below are recommended to thoroughly examine the injured area:

1. One parallel periapical radiograph aimed through the midline to show the two maxillary central incisors.
2. One parallel periapical radiograph aimed at the maxillary right lateral incisors (should also show the right canine and central incisor).
3. One parallel periapical radiograph aimed at the maxillary left lateral incisor (should also show the left canine and central incisor).
4. One maxillary occlusal radiograph.
5. At least one parallel periapical radiograph of the lower incisors centered on the two mandibular centrals. However, other radiographs may be indicated if there are obvious injuries of the

mandibular teeth (eg, similar periapical radiographs as above for the maxillary teeth, mandibular occlusal radiograph).

The radiographs aimed at the maxillary lateral incisors provide different horizontal (mesial and distal) views of each incisor, as well as showing the canine teeth. The occlusal radiograph provides a different vertical view of the injured teeth and the surrounding tissues, which is particularly helpful in the detection of lateral luxations, root fractures, and alveolar bone fractures.^{2,8,9}

The above radiographic series is provided as an example. If other teeth are injured, then the series can be modified to focus on the relevant tooth/teeth. Some minor injuries, such as enamel infractions, may not require all of these radiographs.

Radiographs are necessary to make a thorough diagnosis of dental injuries. Tooth root and bone fractures, for instance, may occur without any clinical signs or symptoms and are frequently undetected when only one radiographic view is used. Additionally, patients sometimes seek treatment several weeks after the trauma occurred when clinical signs of a more serious injury have subsided. Thus, dentists should use their clinical judgment and weigh the advantages and disadvantages of taking several radiographs.

Cone beam computerized tomography (CBCT) provides enhanced visualization of TDIs, particularly root fractures, crown/root fractures, and lateral luxations. CBCT helps to determine the location, extent, and direction of a fracture. In these specific injuries, 3D imaging can be useful and should be considered, if available.⁹⁻¹¹ A guiding principle when considering exposing a patient to ionizing radiations (eg, either 2D or 3D radiographs) is whether the image is likely to change the management of the injury.

4 | PHOTOGRAPHIC DOCUMENTATION

The use of clinical photographs is strongly recommended for the initial documentation of the injury and for follow-up examinations. Photographic documentation allows monitoring of soft tissue healing, assessment of tooth discoloration, the re-eruption of an intruded tooth, and the development of infra-positioning of an ankylosed tooth. In addition, photographs provide medico-legal documentation that could be used in litigation cases.

5 | PULP STATUS EVALUATION: SENSIBILITY AND VITALITY TESTING

5.1 | Sensibility tests

Sensibility testing refers to tests (cold test and electric pulp test) used to determine the condition of the pulp. It is important to understand that sensibility testing assesses neural activity and not vascular supply. Thus, this testing might be unreliable due to a transient lack of neural response or undifferentiation of A-delta nerve fibers in young teeth.¹²⁻¹⁴ The temporary loss of sensibility

is a frequent finding during post-traumatic pulp healing, especially after luxation injuries.¹⁵ Thus, the lack of a response to pulp sensibility testing is not conclusive for pulp necrosis in traumatized teeth.¹⁶⁻¹⁹ Despite this limitation, pulp sensibility testing should be performed initially and at each follow-up appointment in order to determine if changes occur over time. It is generally accepted that pulp sensibility testing should be done as soon as practical to establish a baseline for future comparison testing and follow up. Initial testing is also a good predictor for the long-term prognosis of the pulp.^{12-15,20}

5.2 | Vitality tests

The use of pulse oximetry, which measures actual blood flow rather than the neural response, has been shown to be a reliable non-invasive and accurate way of confirming the presence of a blood supply (vitality) in the pulp.^{14,21} The current use of pulse oximetry is limited due to the lack of sensors specifically designed to fit dental dimensions and the lack of power to penetrate through hard dental tissues.

Laser and ultrasound Doppler flowmetry are promising technologies to monitor pulp vitality.

6 | STABILIZATION/SPLINTING: TYPE AND DURATION

Current evidence supports short-term, passive, and flexible splints for splinting of luxated, avulsed, and root-fractured teeth. In the case of alveolar bone fractures, splinting of the teeth may be used for bone segment immobilization. When using wire-composite splints, physiological stabilization can be obtained with stainless steel wire up to 0.4 mm in diameter.²² Splinting is considered best practice in order to maintain the repositioned tooth in its correct position and to favor initial healing while providing comfort and controlled function.²³⁻²⁵ It is critically important to keep composite and bonding agents away from the gingiva and proximal areas to avoid plaque retention and secondary infection. This allows better healing of the marginal gingiva and bone. Splinting time (duration) will depend on the injury type. Please see the recommendations for each injury type (Tables 1-13).

7 | USE OF ANTIBIOTICS

There is limited evidence for the use of systemic antibiotics in the emergency management of luxation injuries and no evidence that antibiotics improve the outcomes for root-fractured teeth. Antibiotic use remains at the discretion of the clinician as TDIs are often accompanied by soft tissue and other associated injuries, which may require other surgical intervention. In addition, the patient's medical status may warrant antibiotic coverage.^{26,27}

8 | PATIENT INSTRUCTIONS

Patient compliance with follow-up visits and home care contribute to better healing following a TDI. Both patients and parents or guardians should be advised regarding care of the injured tooth/teeth and tissues for optimal healing, prevention of further injury by avoidance of participation in contact sports, meticulous oral hygiene, and rinsing with an antibacterial agent such as chlorhexidine gluconate 0.12%.

9 | FOLLOW UPS AND DETECTION OF POST-TRAUMATIC COMPLICATIONS

Follow ups are mandatory after traumatic injuries. Each follow up should include questioning of the patient about any signs or symptoms, plus clinical and radiographic examinations and pulp sensibility testing. Photographic documentation is strongly recommended. The main post-traumatic complications are as follows: pulp necrosis and infection, pulp space obliteration, several types of root resorption, breakdown of marginal gingiva and bone. Early detection and management of complications improves prognosis.

10 | STAGE OF ROOT DEVELOPMENT—IMMATURE (OPEN APEX) VS MATURE (CLOSED APEX) PERMANENT TEETH

Every effort should be made to preserve the pulp, in both mature and immature teeth. In immature permanent teeth, this is of utmost importance in order to allow continued root development and apex formation. The vast majority of TDIs occur in children and teenagers, where loss of a tooth has lifetime consequences. The pulp of an immature permanent tooth has considerable capacity for healing after a traumatic pulp exposure, luxation injury, or root fracture. Pulp exposures secondary to TDIs are amenable to conservative pulp therapies, such as pulp capping, partial pulpotomy, shallow or partial pulpotomy, and cervical pulpotomy, which aim to maintain the pulp and allow for continued root development.^{28–31} In addition, emerging therapies have demonstrated the ability to revascularize/revitalize teeth by attempting to create conditions allowing for tissue in-growth into the root canals of immature permanent teeth with necrotic pulps.^{32–37}

11 | COMBINED INJURIES

Teeth frequently sustain a combination of several injuries. Studies have demonstrated that crown-fractured teeth, with or without pulp exposure and with a concomitant luxation injury, experience a greater frequency of pulp necrosis and infection.³⁸ Mature permanent teeth that sustain a severe TDI after which pulp necrosis and infection is anticipated are amenable to preventive endodontic treatment.

Since prognosis is worse in combined injuries, the more frequent follow-up regimen for luxation injuries prevails over the less frequent regime for fractures.

12 | PULP CANAL OBLITERATION

Pulp canal obliteration (PCO) occurs more frequently in teeth with open apices which have suffered a severe luxation injury. It usually indicates the presence of viable tissue within the root canal. Extrusion, intrusion, and lateral luxation injuries have high rates of PCO.^{39,40} Subluxated and crown-fractured teeth also may exhibit PCO, although with lower frequency.⁴¹ Additionally, PCO is a common occurrence following root fractures.^{42,43}

13 | ENDODONTIC CONSIDERATIONS FOR LUXATED AND FRACTURED TEETH

13.1 | Fully developed teeth (mature teeth with closed apex)

The pulp may survive after the trauma, but early endodontic treatment is typically advisable for fully developed teeth that have been intruded, severely extruded, or laterally luxated. Calcium hydroxide is recommended as an intra-canal medicament to be placed 1–2 weeks after trauma for up to 1 month followed by root canal filling.⁴⁴ Alternately, a corticosteroid/antibiotic paste can be used as an anti-inflammatory and anti-resorptive intra-canal medicament to prevent external inflammatory (infection-related) resorption. If such a paste is used, it should be placed immediately (or as soon as possible) following repositioning of the tooth and then left in situ for at least 6 weeks.^{45–48} Medicaments should be carefully applied within the root canal system while avoiding contact with the access cavity walls due to possible discoloration of the crown.⁴⁸

13.2 | Incompletely developed teeth (immature teeth with open apex)

The pulp of fractured and luxated immature teeth may survive and heal, or there may be spontaneous pulp revascularization following luxation. Thus, root canal treatment should be avoided unless there is clinical or radiographic evidence of pulp necrosis or periapical infection on follow-up examinations. The risk of infection-related (inflammatory) root resorption should be weighed against the chances of obtaining pulp space revascularization. Such resorption is very rapid in children. Hence, regular follow ups are mandatory so root canal treatment can be commenced as soon as this type of resorption is detected (see below). Incompletely developed teeth that have been intruded and also have a crown fracture (combined traumatic injuries) are at higher risk of pulp necrosis and infection and, therefore, immediate or early root canal treatment might be

considered in these cases. Other endodontic treatment of teeth with incompletely developed roots may involve apexification or pulp space revascularization/revitalization techniques.

13.3 | Endodontic treatment for external inflammatory (infection-related) root resorption

Whenever there is evidence of infection-related (inflammatory) external resorption, root canal treatment should be initiated immediately. The canal should be medicated with calcium hydroxide.⁴⁹ The calcium hydroxide should be placed for 3 weeks and replaced every 3 months until the radiolucencies of the resorptive lesions disappear. Final obturation of the root canal can be performed when bone repair is visible radiographically.

13.4 | Dental dam field isolation during endodontic treatment

Endodontic treatment should always be undertaken under dental dam isolation. The dental dam retainer can be applied on one or more neighboring teeth to avoid further trauma to the injured tooth/teeth and to prevent the risk of fracturing an immature tooth. Dental floss or other stabilizing cords may also be used instead of metal retainers.

14 | CORE OUTCOME SET

The International Association for Dental Traumatology (IADT) recently developed a core outcome set (COS) for traumatic dental injuries (TDIs) in children and adults.⁷ This is one of the first COS developed in dentistry and is underpinned by a systematic review of the outcomes used in the trauma literature and follows a robust consensus methodology. Some outcomes were identified as recurring throughout the different injury types. These outcomes were then identified as “generic” (ie, relevant to all TDIs). Injury-specific outcomes were also determined as those outcomes related only to one or more individual TDIs. Additionally, the study established what, how, when, and by whom these outcomes should be measured. Table 2 in the General Introduction section⁶⁶ of the Guidelines shows the generic and injury-specific outcomes to be recorded at the follow-up review appointments recommended for the different traumatic injuries. Further information for each outcome is described in the original article.⁷

15 | ADDITIONAL RESOURCES

Besides the general recommendations above, clinicians are encouraged to access the IADT's official publication, the journal *Dental Traumatology*, the IADT website (www.iadt-dentaltrauma.org), the free ToothSOS app and the Dental Trauma Guide (www.dentaltraumaguide.org).

TABLE 1 Permanent teeth: Treatment guidelines for enamel infractions

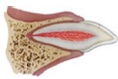
Enamel infraction	Clinical findings	Imaging, radiographic assessment, and findings	Treatment	Follow up	Favorable outcomes	Unfavorable outcomes
 An incomplete fracture (crack or crazing) of the enamel, without loss of tooth structure	<ul style="list-style-type: none"> No sensitivity to percussion or palpation Evaluate the tooth for a possible associated luxation injury or root fracture, especially if tenderness is observed Normal mobility Pulp sensibility tests usually positive 	<ul style="list-style-type: none"> No radiographic abnormalities Recommended radiographs: <ul style="list-style-type: none"> One parallel periapical radiograph Additional radiographs are indicated if signs or symptoms of other potential injuries are present 	<ul style="list-style-type: none"> In case of severe infractions, etching and sealing with bonding resin should be considered to prevent discoloration and bacterial contamination of the infractions. Otherwise, no treatment is necessary 	<ul style="list-style-type: none"> No follow up is needed if it is certain that the tooth suffered an infraction injury only If there is an associated injury such as a luxation injury, that injury-specific follow-up regimen prevails 	<ul style="list-style-type: none"> Asymptomatic Positive response to pulp sensibility testing Continued root development in immature teeth 	<ul style="list-style-type: none"> Symptomatic Pulp necrosis and infection Apical periodontitis Lack of further root development in immature teeth

TABLE 2 Permanent teeth: Treatment guidelines for uncomplicated crown fractures involving enamel only

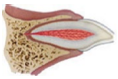
Uncomplicated crown fracture (enamel-only fracture)	Clinical findings	Imaging, radiographic assessment, and findings	Treatment	Follow up	Favorable outcomes	Unfavorable outcomes
 A coronal fracture involving enamel only, with loss of tooth structure	<ul style="list-style-type: none"> • Loss of enamel • No visible sign of exposed dentin • Evaluate the tooth for a possible associated luxation injury or root fracture, especially if tenderness is present • Normal mobility • Pulp sensibility tests usually positive 	<ul style="list-style-type: none"> • Enamel loss is visible • Missing fragments should be accounted for: <ul style="list-style-type: none"> - If fragment is missing and there are soft tissue injuries, radiographs of the lip and/or cheek are indicated to search for tooth fragments and/or foreign materials • Recommended radiographs: <ul style="list-style-type: none"> - One parallel periapical radiograph - Additional radiographs are indicated if signs or symptoms of other potential injuries are present 	<ul style="list-style-type: none"> • If the tooth fragment is available, it can be bonded back on to the tooth • Alternatively, depending on the extent and location of the fracture, the tooth edges can be smoothed, or a composite resin restoration placed 	<ul style="list-style-type: none"> • Clinical and radiographic evaluations are necessary: <ul style="list-style-type: none"> • after 6-8 wk • after 1 y • If there is an associated luxation or root fracture, or the suspicion of an associated luxation injury, the luxation follow-up regimen prevails and should be used. Longer follow ups will be needed 	<ul style="list-style-type: none"> • Asymptomatic • Positive response to pulp sensibility testing • Good quality restoration • Continued root development in immature teeth 	<ul style="list-style-type: none"> • Symptomatic • Pulp necrosis and infection • Apical periodontitis • Loss of restoration • Breakdown of the restoration • Lack of further root development in immature teeth

TABLE 3 Permanent teeth: Treatment guidelines for uncomplicated crown fractures involving enamel and dentin


Uncomplicated crown fracture (enamel-dentin fracture)	Clinical findings	Imaging, radiographic assessment, and findings	Treatment	Follow up	Favorable outcomes	Unfavorable outcomes
 A fracture confined to enamel and dentin without pulp exposure	<ul style="list-style-type: none"> • Normal mobility • Pulp sensibility tests usually positive • No sensitivity to percussion or palpation • Evaluate the tooth for a possible associated luxation injury or root fracture, especially if tenderness is present 	<ul style="list-style-type: none"> • Enamel-dentin loss is visible. • Missing fragments should be accounted for: <ul style="list-style-type: none"> - If fragment is missing and there are soft tissue injuries, radiographs of the lip and/or cheek are indicated to search for tooth fragments and/or foreign materials • Recommended radiographs: <ul style="list-style-type: none"> - One parallel periapical radiograph - Additional radiographs are indicated if signs or symptoms of other potential injuries are present 	<ul style="list-style-type: none"> • If the tooth fragment is available and intact, it can be bonded back on to the tooth. The fragment should be rehydrated by soaking in water or saline for 20 min before bonding • Cover the exposed dentin with glass-ionomer or use a bonding agent • If the exposed dentin is within 0.5 mm of the pulp (pink but no bleeding), place a calcium hydroxide lining and cover with a material such as glass-ionomer 	<ul style="list-style-type: none"> • Clinical and radiographic evaluations are necessary: <ul style="list-style-type: none"> • after 6-8 wk • after 1 y • If there is an associated luxation, root fracture or the suspicion of an associated luxation injury, the luxation follow-up regimen prevails and should be used. Longer follow ups will be needed 	<ul style="list-style-type: none"> • Asymptomatic • Positive response to pulp sensibility testing • Good quality restoration • Continued root development in immature teeth 	<ul style="list-style-type: none"> • Symptomatic • Pulp necrosis and infection • Apical periodontitis. • Lack of further root development in immature teeth • Loss of restoration • Breakdown of the restoration

TABLE 4 Permanent teeth: Treatment guidelines for complicated crown fractures


Complicated crown fracture (enamel-dentin fracture with pulp exposure)	Clinical findings	Imaging, radiographic assessment, and findings	Treatment	Follow up	Favorable outcomes	Unfavorable outcomes
 <p>A fracture confined to enamel and dentin with pulp exposure</p>	<ul style="list-style-type: none"> • Normal mobility • No sensitivity to percussion or palpation. • Evaluate the tooth for a possible associated luxation injury or root fracture, especially if tenderness is present • Exposed pulp is sensitive to stimuli (eg, air, cold, sweets) 	<ul style="list-style-type: none"> • Enamel-dentin loss is visible • Missing fragments should be accounted for: <ul style="list-style-type: none"> - If fragment is missing and there are soft tissue injuries, radiographs of the lip and/or cheek are indicated to search for tooth fragments and/or foreign debris • Recommended radiographs: <ul style="list-style-type: none"> - One parallel periapical radiograph - Additional radiographs are indicated if signs or symptoms of other potential injuries are present 	<ul style="list-style-type: none"> • In patients where teeth have immature roots and open apices, it is very important to preserve the pulp. Partial pulpotomy or pulp capping are recommended in order to promote further root development • Conservative pulp treatment (eg, partial pulpotomy) is also the preferred treatment in teeth with completed root development • Non-setting calcium hydroxide or non-staining calcium silicate cements are suitable materials to be placed on the pulp wound • If a post is required for crown retention in a mature tooth with complete root formation, root canal treatment is the preferred treatment • If the tooth fragment is available, it can be bonded back on to the tooth after rehydration and the exposed pulp is treated • In the absence of an intact crown fragment for bonding, cover the exposed dentin with glass-ionomer or use a bonding agent and composite resin 	<ul style="list-style-type: none"> • Clinical and radiographic evaluations are necessary: <ul style="list-style-type: none"> • after 6-8 wk • after 3 mo • after 6 mo • after 1 y • If there is an associated luxation, root fracture or the suspicion of an associated luxation injury, the luxation follow-up regimen prevails and should be used. Longer follow ups will be needed 	<ul style="list-style-type: none"> • Asymptomatic • Positive response to pulp sensibility testing • Good quality restoration • Continued root development in immature teeth 	<ul style="list-style-type: none"> • Symptomatic • Discoloration • Pulp necrosis and infection • Apical periodontitis • Lack of further root development in immature teeth • Loss of restoration • Breakdown of the restoration

TABLE 5 Permanent teeth: Treatment guidelines for uncomplicated crown-root fractures

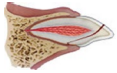
Uncomplicated crown-root fracture (crown-root fracture without pulp exposure)	Clinical findings	Imaging, radiographic assessment, and findings	Treatment	Follow up	Favorable outcomes	Unfavorable outcomes
 <p>A fracture involving enamel, dentin and cementum (Note: Crown-root fractures typically extend below the gingival margin)</p>	<ul style="list-style-type: none"> • Pulp sensibility tests usually positive • Tender to percussion. • Coronal, or mesial or distal, fragment is usually present and mobile • The extent of the fracture (sub- or supra-alveolar) should be evaluated 	<ul style="list-style-type: none"> • Apical extension of fracture usually not visible • Missing fragments should be accounted for: <ul style="list-style-type: none"> - If fragment is missing and there are soft tissue injuries, radiographs of the lip and/or cheek are indicated to search for tooth fragments or foreign debris • Recommended radiographs: <ul style="list-style-type: none"> - One parallel periapical radiograph - Two additional radiographs of the tooth taken with different vertical and/or horizontal angulations - Occlusal radiograph • CBCT can be considered for better visualization of the fracture path, its extent, and its relationship to the marginal bone; also, useful to evaluate the crown-root ratio and to help determine treatment options 	<ul style="list-style-type: none"> • Until a treatment plan is finalized, temporary stabilization of the loose fragment to the adjacent tooth/teeth or to the non-mobile fragment should be attempted • If the pulp is not exposed, removal of the coronal or mobile fragment and subsequent restoration should be considered • Cover the exposed dentin with glass-ionomer or use a bonding agent and composite resin <p>Future Treatment Options:</p> <ul style="list-style-type: none"> • <i>The treatment plan is dependent, in part, on the patient's age and anticipated cooperation. Options include:</i> <ul style="list-style-type: none"> • Orthodontic extrusion of the apical or non-mobile fragment, followed by restoration (may also need periodontal re-contouring surgery after extrusion) • Surgical extrusion • Root canal treatment and restoration if the pulp becomes necrotic and infected • Root submergence • Intentional replantation with or without rotation of the root • Extraction • Autotransplantation 	<ul style="list-style-type: none"> • Clinical and radiographic evaluations are necessary: <ul style="list-style-type: none"> • after 1 wk • after 6-8 wk • after 3 mo • after 6 mo • after 1 y • then yearly for at least 5 ys 	<ul style="list-style-type: none"> • Asymptomatic • Positive response to pulp sensibility testing • Continued root development in immature teeth • Good quality restoration 	<ul style="list-style-type: none"> • Symptomatic • Discoloration • Pulp necrosis and infection • Apical periodontitis • Lack of further root development in immature teeth • Loss of restoration • Breakdown of the restoration • Marginal bone loss and periodontal inflammation

TABLE 6 Permanent teeth: Treatment guidelines for complicated crown-root fractures




Complicated crown-root fracture (crown-root fracture with pulp exposure)	Clinical findings	Imaging, radiographic assessment, and findings	Treatment	Follow up	Favorable outcomes	Unfavorable outcomes
 <p>A fracture involving enamel, dentin, cementum and the pulp (Note: Crown-root fractures typically extend below the gingival margin)</p>	<ul style="list-style-type: none"> • Pulp sensitivity tests usually positive • Tender to percussion. • Coronal, or mesial or distal, fragment is usually present and mobile • The extent of the fracture (sub- or supra-alveolar) should be evaluated 	<ul style="list-style-type: none"> • Apical extension of fracture usually not visible • Missing fragments should be accounted for: <ul style="list-style-type: none"> - If fragment is missing and there are soft tissue injuries, radiographs of the lip and/or cheek are indicated to search for tooth fragments or foreign debris • Recommended radiographs: <ul style="list-style-type: none"> - One parallel periapical radiograph - Two additional radiographs of the tooth taken with different vertical and/or horizontal angulations - Occlusal radiograph • CBCT can be considered for better visualization of the fracture path, its extent, and its relationship to the marginal bone; also useful to evaluate the crown-root ratio and to help determine treatment options 	<ul style="list-style-type: none"> • Until a treatment plan is finalized, temporary stabilization of the loose fragment to the adjacent tooth/teeth or to the non-mobile fragment should be attempted • <i>In immature teeth with incomplete root formation</i>, it is advantageous to preserve the pulp by performing a partial pulpotomy. Rubber dam isolation is challenging but should be tried. <ul style="list-style-type: none"> - Non-setting calcium hydroxide or non-staining calcium silicate cements are suitable materials to be placed on the pulp wound • <i>In mature teeth with complete root formation</i>, removal of the pulp is usually indicated <ul style="list-style-type: none"> - Cover the exposed dentin with glass-ionomer or use a bonding agent and composite resin <p>Future Treatment Options:</p> <ul style="list-style-type: none"> • <i>The treatment plan is dependent, in part, on the patient's age and anticipated co-operation. Options include:</i> <ul style="list-style-type: none"> • Completion of root canal treatment and restoration • Orthodontic extrusion of the apical segment (may also need periodontal re-contouring surgery after extrusion) • Surgical extrusion • Root submergence • Intentional replantation with or without rotation of the root • Extraction • Autotransplantation 	<ul style="list-style-type: none"> • Clinical and radiographic evaluations are necessary: <ul style="list-style-type: none"> • after 1 wk • after 6-8 wk • after 3 mo • after 6 mo • after 1 y • then yearly for at least 5 y 	<ul style="list-style-type: none"> • Asymptomatic • Continued root development in immature teeth • Good quality restoration 	<ul style="list-style-type: none"> • Symptomatic • Pulp necrosis and infection • Apical periodontitis • Lack of further root development in immature teeth • Loss of restoration • Breakdown of the restoration • Marginal bone loss and periodontal inflammation

TABLE 7 Permanent teeth: Treatment guidelines for root fractures

Root fracture	Clinical findings	Imaging, radiographic assessment, and findings	Treatment	Follow up	Favorable outcomes	Unfavorable outcomes
 <p>The coronal segment may be mobile and may be displaced</p> <ul style="list-style-type: none"> The tooth may be tender to percussion Bleeding from the gingival sulcus may be seen Pulp sensibility testing may be negative initially, indicating transient or permanent neural damage <p>A fracture of the root involving dentin, pulp and cementum.</p> <p>The fracture may be horizontal, oblique or a combination of both.</p>	<ul style="list-style-type: none"> The fracture may be located at any level of the root Recommended radiographs: <ul style="list-style-type: none"> One parallel periapical radiograph Two additional radiographs of the tooth taken with different vertical and/or horizontal angulations Occlusal radiograph Root fractures may be undetected without additional imaging In cases where the above radiographs provide insufficient information for treatment planning, CBCT can be considered to determine the location, extent and direction of the fracture 	<ul style="list-style-type: none"> If displaced, the coronal fragment should be repositioned as soon as possible. Check repositioning radiographically Stabilize the mobile coronal segment with a passive and flexible splint for 4 wk. If the fracture is located cervically, stabilization for a longer period of time (up to 4 mo) may be needed Cervical fractures have the potential to heal. Thus, the coronal fragment, especially if not mobile, should not be removed at the emergency visit No endodontic treatment should be started at the emergency visit It is advisable to monitor healing of the fracture for at least one year. Pulp status should also be monitored Pulp necrosis and infection may develop later. It usually occurs in the coronal fragment only. Hence, endodontic treatment of the coronal segment only will be indicated. As root fracture lines are frequently oblique, determination of root canal length may be challenging. An apexification approach may be needed. <p>The apical segment rarely undergoes pathological changes that require treatment</p> <ul style="list-style-type: none"> In mature teeth where the cervical fracture line is located above the alveolar crest and the coronal fragment is very mobile, removal of the coronal fragment, followed by root canal treatment and restoration with a post-retained crown will likely be required. Additional procedures such as orthodontic extrusion of the apical segment, crown lengthening surgery, surgical extrusion or even extraction may be required as future treatment options (similar to those for crown-root fractures outlined above). 	<ul style="list-style-type: none"> Clinical and radiographic evaluations are necessary: <ul style="list-style-type: none"> after 4 wk S⁺ after 6-8 wk after 4 mo S⁺⁺ after 6 mo after 1 y then yearly for at least 5 y 	<ul style="list-style-type: none"> Positive response to pulp sensibility testing; however, a false negative response is possible for several months. Endodontic treatment should not be started solely on the basis of no response to pulp sensibility testing Signs of repair between the fractured segments Normal or slightly more than physiological mobility of the coronal fragment 	<ul style="list-style-type: none"> Symptomatic Extrusion and/or excessive mobility of the coronal segment Radiolucency at the fracture line Pulp necrosis and infection with inflammation in the fracture line 	

Note: S⁺ = splint removal (for mid-root and apical third fractures); S⁺⁺ = splint removal (for cervical third fractures).

TABLE 8 Permanent teeth: Treatment guidelines for alveolar fractures

Alveolar fracture	Clinical Findings	Imaging, radiographic assessment, and findings	Treatment	Follow Up	Favorable outcomes	Unfavorable outcomes
 <p>The fracture involves the alveolar bone and may extend to adjacent bones.</p>	<ul style="list-style-type: none"> The alveolar fracture is complete and extends all the way from the buccal to the palatal bone in the maxilla and from the buccal to the lingual bony surface in the mandible Segment mobility and displacement with several teeth moving together are common findings Occlusal disturbances due to displacement and misalignment of the fractured alveolar segment are often seen Teeth in the fractured segment may not respond to pulp sensibility testing 	<ul style="list-style-type: none"> Fracture lines may be located at any level, from the marginal bone to the root apex Recommended radiographs: <ul style="list-style-type: none"> One parallel periapical radiograph Two additional radiographs of the tooth taken with different vertical and/or horizontal angulations Occlusal radiograph In cases where the above radiographs provide insufficient information for treatment planning, a panoramic radiograph and/or CBCT can be considered to determine the location, extent and direction of the fracture 	<ul style="list-style-type: none"> Reposition any displaced segment Stabilize the segment by splinting the teeth with a passive and flexible splint for 4 wk Suture gingival lacerations if present Root canal treatment is contraindicated at the emergency visit Monitor the pulp condition of all teeth involved, both initially and at follow ups, to determine if or when endodontic treatment becomes necessary 	<ul style="list-style-type: none"> Clinical and radiographic evaluations are necessary: <ul style="list-style-type: none"> after 4 wk S⁺ after 6-8 wk after 4 mo after 6 mo after 1 y then yearly for at least 5 y Bone and soft tissue healing must also be monitored 	<ul style="list-style-type: none"> Positive response to pulp sensibility testing (a false negative response is possible for several months) No signs of pulp necrosis and infection Soft tissue healing Radiographic signs of bone repair Slight tenderness of the bone to palpation may remain at the fracture line and/or on mastication for several months 	<ul style="list-style-type: none"> Symptomatic Pulp necrosis and infection Apical periodontitis Inadequate soft tissue healing Non-healing of the bone fracture External inflammatory (infection-related) resorption

Note: S⁺ = splint removal.

TABLE 9 Permanent teeth: Treatment guidelines for concussion injuries of the teeth

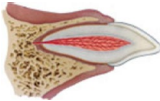
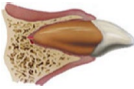
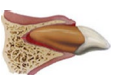
Concussion	Clinical findings	Imaging, radiographic assessment, and findings	Treatment	Follow up	Favorable outcome	Unfavorable outcome
	<ul style="list-style-type: none"> • Normal mobility • The tooth is tender to percussion and touch • The tooth will likely respond to pulp sensibility testing 	<ul style="list-style-type: none"> • No radiographic abnormalities • Recommended radiographs: <ul style="list-style-type: none"> - One parallel periapical radiograph - Additional radiographs are indicated if signs or symptoms of other potential injuries are present 	<ul style="list-style-type: none"> • No treatment is needed. • Monitor pulp condition for at least one year, but preferably longer 	<ul style="list-style-type: none"> • Clinical and radiographic evaluations are necessary: <ul style="list-style-type: none"> • after 4 wk • after 1 y 	<ul style="list-style-type: none"> • Asymptomatic • Positive response to pulp sensibility testing; however, a false negative response is possible for several months. • Endodontic treatment should not be started solely on the basis of no response to pulp sensibility testing • Continued root development in immature teeth • Intact lamina dura 	<ul style="list-style-type: none"> • Symptomatic • Pulp necrosis and infection • Apical periodontitis • No further root development in immature teeth

TABLE 10 Permanent teeth: Treatment guidelines for subluxation injuries of the teeth

Subluxation	Clinical findings	Imaging, radiographic assessment, and findings	Treatment	Follow up	Favorable Outcome	Unfavorable outcome
	<p>The tooth is tender to touch or light tapping</p> <ul style="list-style-type: none"> • Tooth has increased mobility but is not displaced • Bleeding from the gingival crevice may be present • The tooth may not respond to pulp sensibility testing initially indicating transient pulp damage 	<ul style="list-style-type: none"> • Radiographic appearance is usually normal • Recommended radiographs: <ul style="list-style-type: none"> - One parallel periapical radiograph - Two additional radiographs of the tooth taken with different vertical and/or horizontal angulations - Occlusal radiograph 	<ul style="list-style-type: none"> • Normally no treatment is needed • A passive and flexible splint to stabilize the tooth for up to 2 wk may be used but only if there is excessive mobility or tenderness when biting on the tooth • Monitor the pulp condition for at least one year, but preferably longer 	<ul style="list-style-type: none"> • Clinical and radiographic evaluations are necessary: <ul style="list-style-type: none"> • after 2 wk S⁺ • after 12 wk • after 6 mo • after 1 yr 	<ul style="list-style-type: none"> • Asymptomatic • Positive response to pulp sensibility testing; however, a false negative response is possible for several months. Endodontic treatment should not be started solely on the basis of no response to pulp sensibility testing • Continued root development in immature teeth • Intact lamina dura 	<ul style="list-style-type: none"> • Symptomatic • Pulp necrosis and infection • Apical periodontitis • No further root development in immature teeth • External inflammatory (infection-related) resorption – if this type of resorption develops, root canal treatment should be initiated immediately, with the use of calcium hydroxide as an intra-canal medicament. Alternatively, corticosteroid/antibiotic medicament can be used initially, which is then followed by calcium hydroxide


Note: S⁺ = splint removal.

TABLE 11 Permanent teeth: Treatment guidelines for extrusive luxation injuries of the teeth

Extrusive luxation	Clinical findings	Imaging, radiographic assessment, and findings	Treatment	Follow up	Favorable outcome	Unfavorable outcome
 <p>Displacement of the tooth out of its socket in an incisal/axial direction</p>	<ul style="list-style-type: none"> The tooth appears elongated The tooth has increased mobility The tooth will appear elongated incisally Likely to have no response to pulp sensibility tests 	<ul style="list-style-type: none"> Increased periodontal ligament space both apically and laterally Tooth will not be seated in its socket and will appear elongated incisally Recommended radiographs: <ul style="list-style-type: none"> One parallel periapical radiograph Two additional radiographs of the tooth taken with different vertical and/or horizontal angulations Occlusal radiograph 	<ul style="list-style-type: none"> Reposition the tooth by gently pushing it back into the tooth socket under local anesthesia Stabilize the tooth for 2 wk using a passive and flexible splint. If breakdown/fracture of the marginal bone, splint for an additional 4 wk Monitor the pulp condition with pulp sensibility tests If the pulp becomes necrotic and infected, endodontic treatment appropriate to the tooth's stage of root development is indicated 	<ul style="list-style-type: none"> Clinical and radiographic evaluations are necessary: <ul style="list-style-type: none"> after 2 wk S* after 4 wk after 8 wk after 12 wk after 6 mo after 1 y then yearly for at least 5 y Patients (and parents, where relevant) should be informed to watch for any unfavorable outcomes and the need to return to clinic if they observe any Where unfavorable outcomes are identified, treatment is often required. This is outside the scope of these guidelines. Referral to a dentist with the relevant expertise, training and experience is advised 	<ul style="list-style-type: none"> Asymptomatic Clinical and radiographic signs of normal or healed periodontium. Positive response to pulp sensibility testing; however, a false negative response is possible for several months. Endodontic treatment should not be started solely on the basis of no response to pulp sensibility testing No marginal bone loss Continued root development in immature teeth 	<ul style="list-style-type: none"> Symptomatic Pulp necrosis and infection Apical periodontitis Breakdown of marginal bone External inflammatory (infection-related) resorption – if this type of resorption develops, root canal treatment should be initiated immediately, with the use of calcium hydroxide as an intra-canal medicament. Alternatively, corticosteroid/antibiotic medicament can be used initially, which is then followed by calcium hydroxide


Note: S* = splint removal.

TABLE 12 Permanent teeth: Treatment guidelines for lateral luxation injuries of the teeth

Lateral luxation	Clinical findings	Imaging, radiographic assessment, and findings	Treatment	Follow up	Favorable Outcome	Unfavorable outcome
 <p>Displacement of the tooth in any lateral direction, usually associated with a fracture or compression of the alveolar socket wall or facial cortical bone</p>	<ul style="list-style-type: none"> The tooth is displaced, usually in a palatal/lingual or labial direction There is usually an associated fracture of the alveolar bone The tooth is frequently immobile as the apex of the root is "locked" in by the bone fracture Percussion will give a high metallic (ankylotic) sound Likely to have no response to pulp sensibility tests 	<ul style="list-style-type: none"> A widened periodontal ligament space which is best seen on radiographs taken with horizontal angle shifts or occlusal exposures Recommended radiographs: <ul style="list-style-type: none"> One parallel periapical radiograph Two additional radiographs of the tooth taken with different vertical and/or horizontal angulations Occlusal radiograph 	<ul style="list-style-type: none"> Reposition the tooth digitally by disengaging it from its locked position and gently reposition it into its original location under local anesthesia. <ul style="list-style-type: none"> Method: Palpate the gingiva to feel the apex of the tooth. Use one finger to push downwards over the apical end of the tooth, then use another finger or thumb to push the tooth back into its socket Stabilize the tooth for 4 wk using a passive and flexible splint. If breakdown/fracture of the marginal bone or alveolar socket wall, additional splinting may be required Monitor the pulp condition with pulp sensibility tests at the follow-up appointments At about 2 wk post-injury, make an endodontic evaluation: Teeth with incomplete root formation: <ul style="list-style-type: none"> Spontaneous revascularization may occur. If the pulp becomes necrotic and there are signs of inflammatory (infection-related) external resorption, root canal treatment should be started as soon as possible. Endodontic procedures suitable for immature teeth should be used Teeth with complete root formation: <ul style="list-style-type: none"> The pulp will likely become necrotic. Root canal treatment should be started, using a corticosteroid-antibiotic or calcium hydroxide as an intra-canal medicament to prevent the development of inflammatory (infection-related) external resorption 	<ul style="list-style-type: none"> Clinical and radiographic evaluations are necessary: <ul style="list-style-type: none"> after 2 wk after 4 wk S* after 8 wk after 12 wk after 6 mo after 1 y then yearly for at least 5 y Patients (and parents, where relevant) should be informed to watch for any unfavorable outcomes and the need to return to clinic if they observe any Where unfavorable outcomes are identified, treatment is often required. This is outside the scope of these guidelines. Referral to a dentist with the relevant expertise, training and experience is advised 	<ul style="list-style-type: none"> Asymptomatic Clinical and radiographic signs of normal or healed periodontium Positive response to pulp sensibility testing; however, a false negative response is possible for several months. Endodontic treatment should not be started solely on the basis of no response to pulp sensibility testing Marginal bone height corresponds to that seen radiographically after repositioning Continued root development in immature teeth 	<ul style="list-style-type: none"> Symptomatic Breakdown of marginal bone Pulp necrosis and infection Apical periodontitis Ankylosis External replacement resorption External inflammatory (infection-related) resorption External inflammatory (infection-related) resorption – if this type of resorption develops, root canal treatment should be initiated immediately, with the use of calcium hydroxide as an intra-canal medicament. Alternatively, corticosteroid/antibiotic medicament can be used initially, which is then followed by calcium hydroxide

Note: S* = splint removal.

TABLE 13 Permanent teeth: Treatment guidelines for intrusive luxation injuries of the teeth

Intrusive luxation	Clinical findings	Imaging, radiographic assessment, and findings	Treatment	Follow up	Favorable outcome	Unfavorable
 <p>Displacement of the tooth in an apical direction into the alveolar bone</p>	<ul style="list-style-type: none"> The tooth is displaced axially into the alveolar bone The tooth is immobile Percussion will give a high metallic (ankylotic) sound Likely to have no response to pulp sensibility tests 	<ul style="list-style-type: none"> The periodontal ligament space may not be visible for all or part of the root (especially apically) The cemento-enamel junction is located more apically in the intruded tooth than in adjacent non-injured teeth Recommended radiographs: <ul style="list-style-type: none"> One parallel periapical radiograph Two additional radiographs of the tooth taken with different vertical and/or horizontal angulations Occlusal radiograph 	<p>Teeth with incomplete root formation (immature teeth):</p> <ul style="list-style-type: none"> Allow re-eruption without intervention (spontaneous repositioning) for all intruded teeth independent of the degree of intrusion If no re-eruption within 4 wk, initiate orthodontic repositioning Monitor the pulp condition In teeth with incomplete root formation spontaneous pulp revascularization may occur. However, if it is noted that the pulp becomes necrotic and infected or that there are signs of inflammatory (infection-related) external resorption at follow-up appointments, root canal treatment is indicated and should be started as soon as possible when the position of the tooth allows. Endodontic procedures suitable for immature teeth should be used. Parents must be informed about the necessity of follow-up visits <p>Teeth with complete root formation (mature teeth):</p> <ul style="list-style-type: none"> Allow re-eruption without intervention if the tooth is intruded less than 3 mm. If no re-eruption within 8 wk, reposition surgically and splint for 4 wk with a passive and flexible splint Alternatively, reposition orthodontically before ankylosis develops If the tooth is intruded 3-7 mm, reposition surgically (preferably) or orthodontically If the tooth is intruded beyond 7mm, reposition surgically In teeth with complete root formation, the pulp almost always becomes necrotic. Root canal treatment should be started at 2 wk or as soon as the position of the tooth allows, using a corticosteroid-antibiotic or calcium hydroxide as an intra-canal medication. The purpose of this treatment is to prevent the development of inflammatory (infection-related) external resorption 	<ul style="list-style-type: none"> Clinical and radiographic evaluations are necessary: <ul style="list-style-type: none"> after 2 wk after 4 wk S* after 8 wk after 12 wk after 6 mo after 1 y then yearly for at least 5 y Patients (and parents, where relevant) should be informed to watch for any unfavorable outcomes and the need to return to clinic if they observe any Where unfavorable outcomes are identified, treatment is often required. This is outside the scope of these guidelines. Referral to a dentist with the relevant expertise, training and experience is advised 	<ul style="list-style-type: none"> Asymptomatic Tooth in place or is re-erupting Intact lamina dura Positive response to pulp sensibility testing; however, a false negative response is possible for several months. Endodontic treatment should not be started solely on the basis of no response to pulp sensibility testing No signs of root resorption Continued root development in immature teeth 	<ul style="list-style-type: none"> Symptomatic Tooth locked in place/ankylotic tone to percussion Pulp necrosis and infection Apical periodontitis Ankylosis External replacement resorption External inflammatory (infection-related) resorption – if this type of resorption develops, root canal treatment should be initiated immediately, with the use of calcium hydroxide as an intra-canal medicament. Alternatively, corticosteroid/antibiotic medicament can be used initially, which is then followed by calcium hydroxide

Note: S* = splint removal.

CONFLICT OF INTEREST

The authors declare there are no competing interests for the above manuscript. No funding was received for the presented work. Images Courtesy of the Dental Trauma Guide.

ETHICAL STATEMENT

No ethic approval was required for this paper.

ORCID

Cecilia Bourguignon  <https://orcid.org/0000-0003-2753-649X>

Nestor Cohenca  <https://orcid.org/0000-0002-0603-5437>

Eva Lauridsen  <https://orcid.org/0000-0003-0859-7262>

Marie Therese Flores  <https://orcid.org/0000-0003-2412-190X>

Anne C. O'Connell  <https://orcid.org/0000-0002-1495-3983>

Peter F. Day  <https://orcid.org/0000-0001-9711-9638>

Georgios Tsilingaridis  <https://orcid.org/0000-0001-5361-5840>

Paul V. Abbott  <https://orcid.org/0000-0001-5727-4211>

Ashraf F. Fouad  <https://orcid.org/0000-0001-6368-1665>

Bill Kahler  <https://orcid.org/0000-0002-4181-3871>

Liran Levin  <https://orcid.org/0000-0002-8123-7936>

REFERENCES

- Moule A, Cohenca N. Emergency assessment and treatment planning for traumatic dental injuries. *Aust Dent J*. 2016;61(Suppl 1):21-38.
- Andreasen FM, Andreasen JO, Tsukiboshi M, Cohenca N. Examination and diagnosis of dental injuries. In: Andreasen JO, Andreasen FM, Andersson L, editors. *Textbook and color atlas of traumatic injuries to the teeth*, 5th edn. Oxford, UK: Wiley Blackwell; 2019. p. 295-326.
- Andreasen JO, Bakland L, Flores MT, Andreasen FM, Andersson L. *Traumatic dental injuries. A manual*, 3rd edn. Chichester, UK: Wiley-Blackwell; 2011.
- Lauridsen E, Hermann NV, Gerds TA, Ahrensburg SS, Kreiborg S, Andreasen JO. Combination injuries 1. The risk of pulp necrosis in permanent teeth with concussion injuries and concomitant crown fractures. *Dent Traumatol*. 2012;28:364-70.
- Lauridsen E, Hermann NV, Gerds TA, Ahrensburg SS, Kreiborg S, Andreasen JO. Combination injuries 2. The risk of pulp necrosis in permanent teeth with subluxation injuries and concomitant crown fractures. *Dent Traumatol*. 2012;28:371-8.
- Lauridsen E, Hermann NV, Gerds TA, Ahrensburg SS, Kreiborg S, Andreasen JO. Combination injuries 3. The risk of pulp necrosis in permanent teeth with extrusion or lateral luxation and concomitant crown fractures without pulp exposure. *Dent Traumatol*. 2012;28:379-85.
- Kenny KP, Day PF, Sharif MO, Parashos P, Lauridsen E, Feldens CA, et al. What are the important outcomes in traumatic dental injuries? An international approach to the development of a core outcome set. *Dent Traumatol*. 2018;34:4-11.
- Molina JR, Vann WF Jr, McIntyre JD, Trope M, Lee JY. Root fractures in children and adolescents: diagnostic considerations. *Dent Traumatol*. 2008;24:503-9.
- Cohenca N, Silberman A. Contemporary imaging for the diagnosis and treatment of traumatic dental injuries: a review. *Dent Traumatol*. 2017;33:321-8.
- Cohenca N, Simon JH, Mathur A, Malfaz JM. Clinical indications for digital imaging in dento-alveolar trauma. Part 2: root resorption. *Dent Traumatol*. 2007;23:105-13.
- Cohenca N, Simon JH, Roges R, Morag Y, Malfaz JM. Clinical indications for digital imaging in dento-alveolar trauma. Part 1: traumatic injuries. *Dent Traumatol*. 2007;23:95-104.
- Fulling HJ, Andreasen JO. Influence of maturation status and tooth type of permanent teeth upon electrometric and thermal pulp testing. *Scand J Dent Res*. 1976;84:286-90.
- Fuss Z, Trowbridge H, Bender IB, Rickoff B, Sorin S. Assessment of reliability of electrical and thermal pulp testing agents. *J Endod*. 1986;12:301-5.
- Gopikrishna V, Tinagupta K, Kandaswamy D. Comparison of electrical, thermal, and pulse oximetry methods for assessing pulp vitality in recently traumatized teeth. *J Endod*. 2007;33:531-5.
- Bastos JV, Goulart EM, de Souza Cortes MI. Pulpal response to sensibility tests after traumatic dental injuries in permanent teeth. *Dent Traumatol*. 2014;30:188-92.
- Dummer PM, Hicks R, Huws D. Clinical signs and symptoms in pulp disease. *Int Endod J*. 1980;13:27-35.
- Kaletsky T, Furedi A. Reliability of various types of pulp testers as a diagnostic aid. *J Am Dent Assoc*. 1935;22:1559-74.
- Teitler D, Tzadik D, Eidelman E, Chosack A. A clinical evaluation of vitality tests in anterior teeth following fracture of enamel and dentin. *Oral Surg Oral Med Oral Pathol*. 1972;34:649-52.
- Zadik D, Chosack A, Eidelman E. The prognosis of traumatized permanent anterior teeth with fracture of the enamel and dentin. *Oral Surg Oral Med Oral Pathol*. 1979;47:173-5.
- Alghaithy RA, Qualtrough AJ. Pulp sensibility and vitality tests for diagnosing pulpal health in permanent teeth: a critical review. *Int Endod J*. 2017;50:135-42.
- Gopikrishna V, Tinagupta K, Kandaswamy D. Evaluation of efficacy of a new custom-made pulse oximeter dental probe in comparison with the electrical and thermal tests for assessing pulp vitality. *J Endod*. 2007;33:411-4.
- Kwan SC, Johnson JD, Cohenca N. The effect of splint material and thickness on tooth mobility after extraction and replantation using a human cadaveric model. *Dental Traumatol*. 2012;28:277-81.
- Kahler B, Heithersay GS. An evidence-based appraisal of splinting luxated, avulsed and root-fractured teeth. *Dent Traumatol*. 2008;24:2-10.
- Oikarinen K, Andreasen JO, Andreasen FM. Rigidity of various fixation methods used as dental splints. *Endod Dent Traumatol*. 1992;8:113-9.
- Andreasen JO, Andreasen FM, Mejare I, Cvek M. Healing of 400 intra-alveolar root fractures. 2. Effect of treatment factors such as treatment delay, repositioning, splinting type and period and antibiotics. *Dental Traumatol*. 2004;20:203-11.
- Hammarstrom L, Blomlof L, Feiglin B, Andersson L, Lindskog S. Replantation of teeth and antibiotic treatment. *Endod Dent Traumatol*. 1986;2:51-7.
- Andreasen JO, Storgaard Jensen S, Sae-Lim V. The role of antibiotics in presenting healing complications after traumatic dental injuries: a literature review. *Endod Topics*. 2006;14:80-92.
- Cvek M. A clinical report on partial pulpotomy and capping with calcium hydroxide in permanent incisors with complicated crown fracture. *J Endod*. 1978;4:232-7.
- Fuks AB, Cosack A, Klein H, Eidelman E. Partial pulpotomy as a treatment alternative for exposed pulps in crown-fractured permanent incisors. *Endod Dent Traumatol*. 1987;3:100-2.
- Fuks AB, Gavra S, Chosack A. Long-term followup of traumatized incisors treated by partial pulpotomy. *Pediatr Dent*. 1993;15:334-6.
- Bimstein E, Rotstein I. Cvek pulpotomy - revisited. *Dent Traumatol*. 2016;32:438-42.
- Chueh LH, Ho YC, Kuo TC, Lai WH, Chen YH, Chiang CP. Regenerative endodontic treatment for necrotic immature permanent teeth. *J Endod*. 2009;35:160-4.

33. Hagglund M, Walden M, Bahr R, Ekstrand J. Methods for epidemiological study of injuries to professional football players: developing the UEFA model. *Br J Sports Med.* 2005;39:340–6.
34. Huang GT. A paradigm shift in endodontic management of immature teeth: conservation of stem cells for regeneration. *J Dent.* 2008;36:379–86.
35. Jung IY, Lee SJ, Hargreaves KM. Biologically based treatment of immature permanent teeth with pulpal necrosis: a case series. *J Endod.* 2008;34:876–87.
36. Thibodeau B, Teixeira F, Yamauchi M, Caplan DJ, Trope M. Pulp revascularization of immature dog teeth with apical periodontitis. *J Endod.* 2007;33:680–9.
37. Trope M. Treatment of the immature tooth with a non-vital pulp and apical periodontitis. *Dent Clin North Am.* 2010;54:313–24.
38. Robertson A, Andreasen FM, Andreasen JO, Noren JG. Long-term prognosis of crown-fractured permanent incisors. The effect of stage of root development and associated luxation injury. *Int J Paediatr Dent.* 2000;10:191–9.
39. Holcomb JB, Gregory WB Jr. Calcific metamorphosis of the pulp: its incidence and treatment. *Oral Surg Oral Med Oral Pathol.* 1967;24:825–30.
40. Neto JJ, Gondim JO, de Carvalho FM, Giro EM. Longitudinal clinical and radiographic evaluation of severely intruded permanent incisors in a pediatric population. *Dent Traumatol.* 2009;25:510–4.
41. Robertson A. A retrospective evaluation of patients with uncomplicated crown fractures and luxation injuries. *Endod Dent Traumatol.* 1998;14:245–56.
42. Andreasen FM, Andreasen JO, Bayer T. Prognosis of root-fractured permanent incisors-prediction of healing modalities. *Endod Dent Traumatol.* 1989;5:11–22.
43. Amir FA, Gutmann JL, Witherspoon DE. Calcific metamorphosis: a challenge in endodontic diagnosis and treatment. *Quintessence Int.* 2001;32:447–55.
44. Cvek M. Prognosis of luxated non-vital maxillary incisors treated with calcium hydroxide and filled with gutta percha. *Endod Dent Traumatol.* 1992;8:45–55.
45. Abbott PV. Prevention and management of external inflammatory resorption following trauma to teeth. *Aust Dent J.* 2016;61(Suppl. 1):S82–S94.
46. Bryson EC, Levin L, Banchs F, Abbott PV, Trope M. Effect of immediate intracanal placement of Iedermix paste on healing of replanted dog teeth after extended dry times. *Dent Traumatol.* 2002;18:316–21.
47. Chen H, Teixeira FB, Ritter AL, Levin L, Trope M. The effect of intracanal anti-inflammatory medicaments on external root resorption of replanted dog teeth after extended extra-oral dry time. *Dent Traumatol.* 2008;24:74–8.
48. Day PF, Gregg TA, Ashley P, Welbury RR, Cole BO, High AS, et al. Periodontal healing following avulsion and replantation of teeth: A multi-centre randomized controlled trial to compare two root canal medicaments. *Dent Traumatol.* 2012;28:55–64.
49. Trope M, Moshonov J, Nissan R, Buxt P, Yesilsoy C. Short vs. Long-term calcium hydroxide treatment of established inflammatory root resorption in replanted dog teeth. *Endod Dent Traumatol.* 1995;11:124–8.
50. Andreasen JO, Andreasen FM, Skeie A, Hjorting-Hansen E, Schwartz O. Effect of treatment delay upon pulp and periodontal healing of traumatic dental injuries – a review article. *Dent Traumatol.* 2002;18:116–28.
51. Andreasen JO, Bakland LK, Andreasen FM. Traumatic intrusion of permanent teeth. Part 3. A clinical study of the effect of treatment variables such as treatment delay, method of repositioning, type of splint, length of splinting and antibiotics on 140 teeth. *Dent Traumatol.* 2006;22:99–111.
52. Andreasen JO, Bakland LK, Andreasen FM. Traumatic intrusion of permanent teeth. Part 2. A clinical study of the effect of preinjury and injury factors, such as sex, age, stage of root development, tooth location, and extent of injury including number of intruded teeth on 140 intruded permanent teeth. *Dent Traumatol.* 2006;22:90–8.
53. Andreasen JO, Bakland LK, Matras RC, Andreasen FM. Traumatic intrusion of permanent teeth. Part 1. An epidemiological study of 216 intruded permanent teeth. *Dent Traumatol.* 2006;22:83–9.
54. Welbury R, Kinirons MJ, Day P, Humphreys K, Gregg TA. Outcomes for root-fractured permanent incisors: a retrospective study. *Ped Dent.* 2002;24:98–102.
55. Andreasen JO, Andreasen FM, Mejare I, Cvek M. Healing of 400 intra-alveolar root fractures. 1. Effect of pre-injury and injury factors such as sex, age, stage of root development, fracture type, location of fracture and severity of dislocation. *Dent Traumatol.* 2004;20:192–202.
56. Andreasen JO, Hjorting-Hansen E. Intraalveolar root fractures: radiographic and histologic study of 50 cases. *J Oral Surg.* 1967;25:414–26.
57. Cvek M, Andreasen JO, Borum MK. Healing of 208 intra-alveolar root fractures in patients aged 7–17 years. *Dent Traumatol.* 2001;17:53–62.
58. Bakland LK. Revisiting traumatic pulpal exposure: materials, management principles, and techniques. *Dent Clin North Am.* 2009;53:661–73.
59. Bogen G, Kim JS, Bakland LK. Direct pulp capping with mineral trioxide aggregate: an observational study. *J Am Dent Assoc.* 2008;139:305–15.
60. Cavalleri G, Zerman N. Traumatic crown fractures in permanent incisors with immature roots: a follow-up study. *Endod Dent Traumatol.* 1995;11:294–6.
61. About I, Murray PE, Franquin JC, Remusat M, Smith AJ. The effect of cavity restoration variables on odontoblast cell numbers and dental repair. *J Dent.* 2001;29:109–17.
62. Murray PE, Smith AJ, Windsor LJ, Mjor IA. Remaining dentine thickness and human pulp responses. *Int Endod J.* 2003;36:33–43.
63. Subay RK, Demirci M. Pulp tissue reactions to a dentin bonding agent as a direct capping agent. *J Endod.* 2005;31:201–4.
64. Berthold C, Thaler A, Petschelt A. Rigidity of commonly used dental trauma splints. *Dent Traumatol.* 2009;25:248–55.
65. von Arx T, Filippi A, Lussi A. Comparison of a new dental trauma splint device (TTS) with three commonly used splinting techniques. *Dent Traumatol.* 2001;17:266–74.
66. Levin L, Day P, Hicks L, O'Connell AC, Fouad AF, Bourguignon C, et al. International Association of Dental Traumatology guidelines for the management of traumatic dental injuries: General Introduction. *Dent Traumatol.* 2020;36:309–13.

How to cite this article: Bourguignon C, Cohenca N, Lauridsen E, et al. International Association of Dental Traumatology guidelines for the management of traumatic dental injuries: 1. Fractures and luxations. *Dent Traumatol.* 2020;36:314–330. <https://doi.org/10.1111/edt.12578>